

Received: 2004.04.08
Accepted: 2004.05.06
Published: 2004.07.09

Spontaneous regression of pancreatic cancer

**Stephen A Hopton Cann¹, Hal D Gunn², Johannes P. van Netten³,
 Christiaan van Netten¹**

¹Department of Health Care and Epidemiology, University of British Columbia, Vancouver, Canada,

²Centre for Integrated Healing, Vancouver, Canada,

³Department of Biology, University of Victoria, Victoria, Canada

Summary

Background:

Spontaneous tumor regression has been the object of considerable interest and speculation for hundreds, if not thousands of years. It has been reported following a wide diversity of infections. We describe a case of spontaneous pancreatic cancer regression and review the relevant literature.

Case report:

A 50-year-old male presented with a history of weight loss, anorexia and discomfort after meals. Oncology workup revealed pancreatic adenocarcinoma (T2N1M0, stage IIIb). A two-week regimen of radiotherapy combined with seven weeks of gemcitabine failed to alter the progress of the disease. However, a subsequent perforated duodenal ulcer was followed by severe peritonitis, fever, and tumor regression.

Conclusions:

A review of the literature uncovered only three previous cases of spontaneous pancreatic cancer regression. The authors discuss the importance of the acute febrile immune response, which appears to be an underappreciated mediator of tumor regression.

Key words:

fever • infection • leukocytes • pancreatic neoplasms • spontaneous regression

Full-text PDF:

http://www.crcpr-online.com/pub/case/vol_5/5499.pdf

Word count:

1482

Tables:

-

Figures:

1

References:

22

Author's address:

Stephen A Hopton Cann, Department of Health Care and Epidemiology, University of British Columbia, Vancouver, BC V6T 1Z3, Canada, tel 604-822-5973 fax 604-822-4994, e-mail:stephen.hopton.cann@ubc.ca

BACKGROUND

Spontaneous tumor regression has been defined as the partial or complete disappearance of malignant disease without treatment or in the “presence of therapy which is considered inadequate to exert a significant influence on neoplastic disease” [1]. A broad diversity of mechanisms has been hypothesized as reasons for regression. In particular, this phenomenon has been observed following a wide spectrum of infections including those due to bacterial, viral, fungal and protozoal pathogens [2]. Such regressions are often noted during the acute febrile phase [2]. Here we report a case of spontaneous pancreatic regression, which followed a severe intra-abdominal infection and persistent fever.

CASE REPORT

A 95 kg, 50-year-old man was seen on December 31, 2000 with a three-month history of weight loss (12 kg), anorexia, and discomfort after meals. On January 4, an abdominal ultrasound identified a hypoechoic mass in the body of the pancreas. The tumor marker, CA 19-9, was slightly elevated at 38 U/ml (normal <35 U/ml). The CA 19-9 was monitored periodically from that time onward (Fig. 1). A computed tomography (CT) scan confirmed a mass in the body of the pancreas measuring

6.5x4x4 cm. On February 5, a CT guided biopsy was positive for pancreatic adenocarcinoma (T2N1M0, stage IIIb). A subsequent CT scan in April revealed a further 50-60% increase in tumor volume. The disease was considered inoperable and chemotherapy with seven weekly doses of gemcitabine (400 mg/m²/week) was administered from May 4 to June 14. During the second week, the patient began a two-week course of 30 Gy fractionated radiotherapy (3 Gy/fraction, 10 fractions).

By June 29, the CA 19-9 had progressively increased to 147 U/ml, while a CT scan showed no change in tumor size. The patient, constantly nauseated and unable to eat, lost a further 14 kg since his therapy began. The treatment was considered a failure. He was given a one-time dose of mitomycin C (20 mg) and sent home. Two days later, the patient developed acute abdominal pain following breakfast and was admitted to hospital. At surgery, the patient was found to have a perforated duodenal ulcer with contamination of the abdomen. Intermittent fevers (~38°C) accompanied the postoperative course. Ten days following surgery his abdomen became distended, with a purulent discharge exuding from the incision. In view of patient's decline in health, a second operation was contraindicated and the patient was given intravenous antibiotics. Pneumonia and recurrent fevers (38-39.5°C) followed.

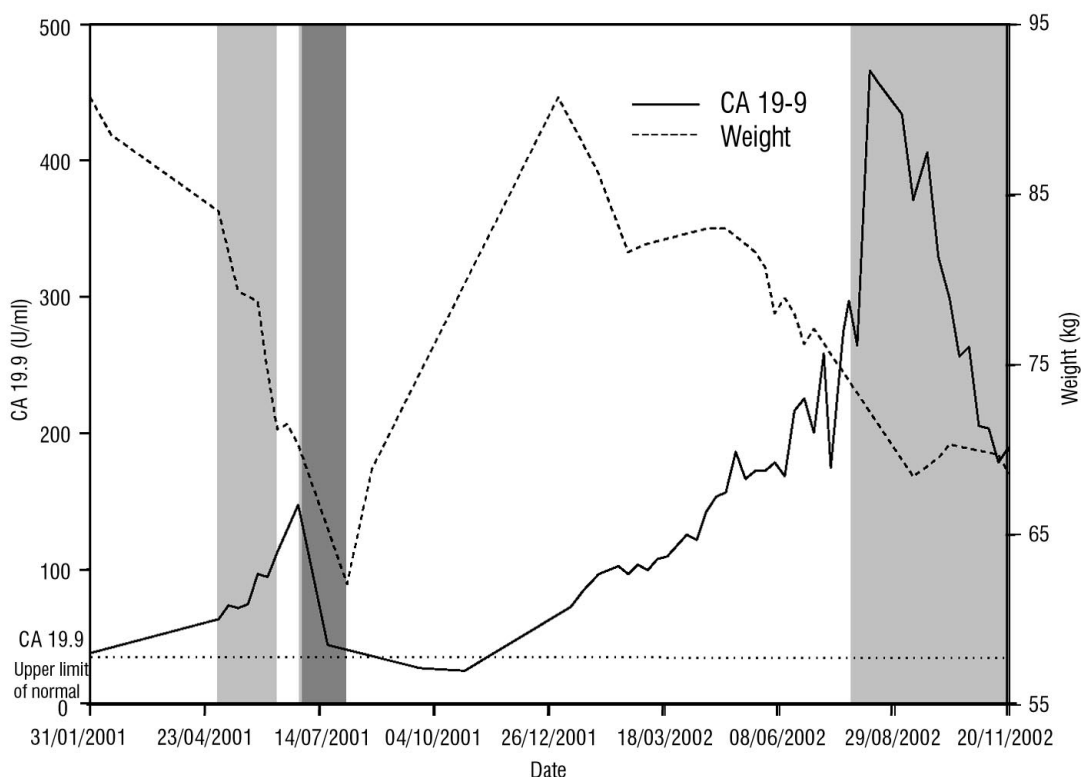


Figure 1. The serum CA 19-9 contrasted to patient weight highlights the dramatic recovery in weight the patient experienced following his infection. Light gray boxes correspond to periods of chemotherapy, and dark gray box, period of hospitalization for infection.

Recovery was considered doubtful. However by August 2 the patient, weak and emaciated (62 kg), was discharged to home care. His recuperation and weight gain was surprisingly rapid. By September, the CA 19-9 level was normal (27 U/ml) and a positron emission tomography (PET) scan was negative for any focal disease. An ultrasound, however, confirmed residual tumor, although it had regressed by approximately 70% from June.

In January 2002, an elevated CA 19-9 and subsequent PET scan confirmed a relapse. Overall, there was little change in the patient's condition for the next six months. Chemotherapy was restarted on July 29, oxaliplatin and 5-fluorouracil initially, then gemcitabine on August 12. The patient's health progressively deteriorated and therapy was discontinued on November 20. The patient died in March 2003, 19 months following his febrile infection.

Aside from the infection, other factors may or may not have been relevant to his tumor regression. Shortly after his diagnosis, the patient changed to a vegetarian diet and intermittently used a variety of alternative therapies: Chinese herbs, high-dose vitamin C and other antioxidant vitamins, hydrogen peroxide, and ginseng. Alternatively, the single dose, single agent, systemic administration of mitomycin could have been a factor, but unlikely the primary cause of the regression [3].

DISCUSSION

Only three previous cases [4-6] of spontaneous pancreatic cancer regression have been reported. The first reported case [4] was a patient admitted to hospital in December 1934. She presented with jaundice, severe pain, nausea, chills, and a high fever. Exploratory laparotomy and biopsy confirmed inoperable pancreatic carcinoma. Her recovery spanned two months before she could return to work. She remained in good health, dying seven and a half years later of a pulmonary embolism. Autopsy failed to find any trace of cancer. The second case [5] was a male with a two-month history of ulcer pain and diarrhea. At exploration, a large tumor of the pancreatic head extending into the liver with involved lymph nodes was observed and confirmed by biopsy. No further manipulation was performed. By the fourth month following surgery, he was asymptomatic. An upper gastrointestinal exam demonstrated healing of the ulcer. Examined six years later, the patient remained without symptoms. The final case [6], a 21-year-old male was admitted in April 1962. He had a three-

month history of jaundice, presenting with malaise, anorexia, and fever. A liver biopsy was followed by abdominal pain, tachycardia, and a decrease in blood pressure. Transferred to another hospital for treatment, his temperature was 38.1°C on admission. Bile peritonitis developed following the rent in the liver. Exploratory surgery to repair the rupture revealed acute cholangitis and pericholangitis. When reoperated on seven weeks later, a diagnosis of pancreatic adenocarcinoma was made. A T tube placed in the common duct improved symptoms and he was discharged after one month. Upon his return three weeks later, a Whipple operation was considered but abandoned during surgery. He made a slow recovery at home over a period of six months with no recurrence at the time of reporting. Unfortunately, details on the duration and intensity of fever or infection over the course of the illness in most of these cases were not provided. This is not surprising as in a review of case reports of spontaneous regression from 1966 to 1987, Challis and Stam [7] reported that more than 40% of authors failed to specify any causative factors. Such a failure may explain the slow progress that has occurred in understanding the mechanisms behind this phenomenon.

Although current reviews of this phenomenon describe spontaneous regression as a rare event [8-10], reviews from previous eras present a different picture. For example, Tanchou in 1844 remarked that "one knows that often the affected lymph nodes and primary growths disappear during the course of concurrent illness, never to return" [11]; Handley in 1909 commented that such reports are "far from being anomalous and exceptional" [12]; and finally in 1903, Coley [13] was surprised to uncover the superior early results of operations for bone sarcomas in 165 patients reported by Gross in 1879 [14]. He concluded that the only plausible explanation was the greater occurrence of postoperative infections during that pre-antiseptic era [13]. Similarly, the comparative rarity of spontaneous regressions today may result from the immunosuppressive nature of modern conventional cancer therapies [15]. For example, changes in patient management that have transpired this past century include: introduction of aseptic surgical techniques, reducing the occurrence of the postoperative infections; prophylactic antibiotics, which reduces both the occurrence of infections as well as the severity and duration of those infections that do arise; immunosuppressive treatment regimens (i.e. chemotherapy and radiotherapy); and finally, employment of antipyretics for the treatment of febrile patients.

A number of authors have marveled at the diversity of organisms that have been associated with spontaneous regression [15-17]. For example, in his 1918 review of over 300 cases, Rohdenburg states "observation shows that recession has occurred after small-pox, pneumonia, malaria, and acute tuberculosis. No one organism is, therefore, specific in causing recession" [17]. He goes on to note that in those cases given in detail, there is one common symptom – sustained high temperature lasting for several days or more – a finding also reported by others [2,17-19]. In contrast, recurrence is often observed shortly after recession of the acute febrile phase [2,16]. This evidence, and observations of rapid tumor regression following infection (sometimes within hours), suggests that the innate, rather than adaptive, immune response is a primary mediator of tumor regression in such cases [2]. Unfortunately, even during cancer immunotherapy, an acute febrile reaction is often regarded as a side effect to be suppressed, rather than an integral component of the immune response [15].

The immune system plays an important dual role in maintaining the integrity of the host. Leukocytes are primarily recognized for their role in defense against foreign pathogens; however, these cells play an equally important role in tissue repair [15]. During

wound healing, leukocytes are actively engaged in tissue remodeling, growth factor production, and the induction of new blood and lymphatic vessels. However, like wounded tissue, expanding tumors release a variety of cytokines that attract leukocytes and signal that increased oxygen and nutrients levels are required. As infiltrating leukocytes represent a significant proportion of the cellular mass of rapidly growing carcinomas [20,21], serendipitous infection within the vicinity of such immune cells could reactivate their defensive activities and induce tumor regression [2,15].

CONCLUSIONS

Regression in the present case appeared to coincide with a prolonged febrile infection similar to that often observed in many other cases of spontaneous regression [2,16,22]. Moreover, it appears significant that in this patient the duodenal perforation occurred in the vicinity of the tumor. This could facilitate direct stimulation of the intratumoral leukocyte population. Perhaps, complete regression could have been obtained by simulating his previous febrile infection through repeated inoculations with a killed bacterial vaccine [2].

REFERENCES

1. Everson TC, Cole WH. Spontaneous regression of cancer. Philadelphia, PA: JB Saunders, 1968, p. 4.
2. Hopton Cann SA, van Netten JP, van Netten C. Dr William Coley and tumour regression: a place in history or in the future? *Postgraduate Med J* 2003;79:672-680.
3. Fennelly D, Kelsen DP. The role of chemotherapy in the treatment of adenocarcinoma of the pancreas. *Hepatogastroenterology* 1996;43:356-362.
4. Shapiro SL. Spontaneous regression of cancer. *Eye Ear Nose Throat Mon* 1967;46:1306-1310.
5. Eidemiller LR, Fletcher WS, Dennis DL, et al. Spontaneous remission of proven cancer. *Northwest Med* 1971;70:539-543.
6. Tchertkoff V, Hauser AD. Carcinoma of head of pancreas with spontaneous regression. *N Y State J Med* 1974;74:1814-1817.
7. Challis GB, Stam HJ. The spontaneous regression of cancer. A review of cases from 1900 to 1987. *Acta Oncol* 1990;29:545-550.
8. Chang WY. Complete spontaneous regression of cancer: four case reports, review of literature, and discussion of possible mechanisms involved. *Hawaii Med J* 2000;59:379-387.
9. Takeda Y, Togashi H, Shinzawa H, et al. Spontaneous regression of hepatocellular carcinoma and review of literature. *J Gastroenterol Hepatol* 2000;15:1079-1086.
10. Nagorsen D, Marincola FM, Kaiser HE. Bacteria-related spontaneous and therapeutic remission of human malignancies. *In Vivo* 2002;16:551-556.
11. Tanchou SL. Recherches sur le traitement médical des tumeurs cancéreuses du sein. Ouvrage pratique basé sur trois cents observations (extraits d'un grand nombre d'auteurs). Paris: G Baillière, 1844.
12. Handley WS. The natural cure of cancer. *Brit Med J* 1909;1:582.
13. Coley WB. Amputation of the hip-joint for sarcoma with a report of seven cases without mortality. *Trans South Surg Gynecol Assoc* 1903;16:77-96.
14. Gross SW. Sarcoma of the long bones based upon a study of one hundred and sixty-five cases. *Am J Med Sci* 1879;78:17-7857.
15. Hopton Cann SA, van Netten JP, van Netten C, et al. Spontaneous regression: a hidden treasure buried in time. *Med Hypotheses* 2002;58:115-119.
16. Nauts HC. The beneficial effects of bacterial infections on host resistance to cancer: end results in 449 cases, 2nd ed. Monograph No. 8. New York, NY: Cancer Research Institute, 1980.
17. Rohdenburg GL. Fluctuations in the growth energy of tumors in man, with especial reference to spontaneous recession. *J Cancer Res* 1918;3:193-225.
18. Miller TR, Nicholson JT. End results in reticulum cell sarcoma of bone treated by bacterial toxin therapy alone or combined with surgery and/or radiotherapy (47 cases) or with concurrent infection (5 cases). *Cancer* 1971;27:524-548.
19. Stephenson HE Jr, Delmez JA, Renden DI, et al. Host immunity and spontaneous regression of cancer evaluated by computerized data reduction study. *Surg Gynecol Obstet* 1971;133:649-655.
20. Ben-Baruch A. Host microenvironment in breast cancer development: inflammatory cells, cytokines and chemokines in breast cancer progression: reciprocal tumor-microenvironment interactions. *Breast Cancer Res* 2003;5:31-36.
21. Yu JL, Rak JW. Host microenvironment in breast cancer development: inflammatory and immune cells in tumour angiogenesis and arteriogenesis. *Breast Cancer Res* 2003;5:83-88.
22. Maywald O, Buchheidt D, Bergmann J, et al. Spontaneous remission in adult acute myeloid leukemia in association with systemic bacterial infection-case report and review of the literature. *Ann Hematol* 2004;83:189-194.